

Castleman's Disease (Giant Lymphnode Hyperplasia of the Mediastinum)

Rafael Martin D. Hilado, MD

Background --- Castleman's Disease is a rare, benign, atypical lymphoproliferative disorder of unknown etiology characterized by hypervascular lymphoid hyperplasia. It may occur anywhere where there is lymphoid tissue but is most commonly seen in the anterior mediastinum. It may either be localized or disseminated and further subdivided into hyaline-vascular, plasma cell, and mixed histopathological types. Resection of the mass is curative in the majority of cases.

Case --- We present a case of disseminated Castleman's disease occurring in a 19 years old female patient who presented with chest pain and chronic non-productive cough, and an intensely enhancing, non-calcified, lobulated mass in the left anterior mediastinum on Chest CT scan.

Conclusion --- Clinicians should be aware that Castleman's disease should be considered as one of the differentials in patients presenting with mediastinal mass. *Phil Heart Center J 2012; 16(2):71-74*

Key Words: Castleman's Disease ■ Mediastinal mass

Castleman's Disease (CD) is a disease of the lymph nodes and is encountered rarely. It was originally described by Benjamin Castleman in 1956.¹ Literature has described three histological variants: hyaline-vascular (90%), which is observed in young patients; plasma cell, which affects mainly adults and elderly people; and the mixed variant type. Clinically, the disease has been classified into a localized and a disseminated form.²⁻⁴ It may occur in various locations but frequently occurs in the posterior mediastinum. It usually presents as an asymptomatic, well circumscribed, solitary mass. The author reports a Castleman's disease occurring in the anterior mediastinum of a 19 years old female.

Case

This is a case of a 19-year old, female nonsmoker with no history of pulmonary tuberculosis, who was admitted for evaluation of a mediastinal mass. The present illness started few months prior to admission when the patient experienced chest pains associate with nonproductive cough. No

fever, colds, difficulty of breathing or weight loss were noted. Chest x-ray revealed presence of a probable mediastinal mass. The patient was advised further work up and was subsequently referred to our institution.

Physical examination was unremarkable except for presence of lymphadenopathies in the cervical and left supraclavicular areas. She had symmetrical chest expansion and auscultation revealed vesicular breath sounds with no crackles noted. The precordium was adynamic with the apex beat at the 5th intercostal space left mid clavicular line. Neurologic examination was unremarkable.

On admission, chest x-ray revealed a lobulated soft tissue density obscuring the aortic knob and extending down to the left atrial appendage and appears to be located in the anterior mediastinum on lateral view. (*Figure 1*)

Chest CT scan with contrast was done that showed an intensely enhancing, non-calcified, lobulated mass, measuring approximately 2.4 cm x 5.9 cm x 6.7 cm (AP x W x CC) in the left anterior mediastinum at the level of the aortic

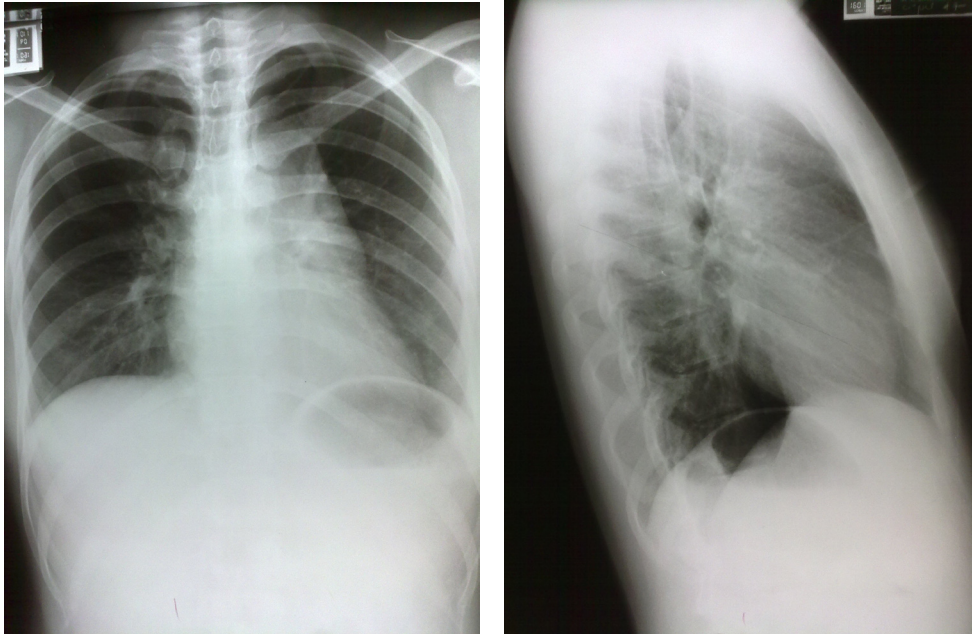


Figure 1. Chest X-ray PA and Lateral Views of a 19 y. o. female with mediastinal mass. Chest radiograph shows lobulated soft tissue density obscuring the aortic knob and extending down to the left atrial appendage, and appears to be located in the anterior mediastinum on lateral view

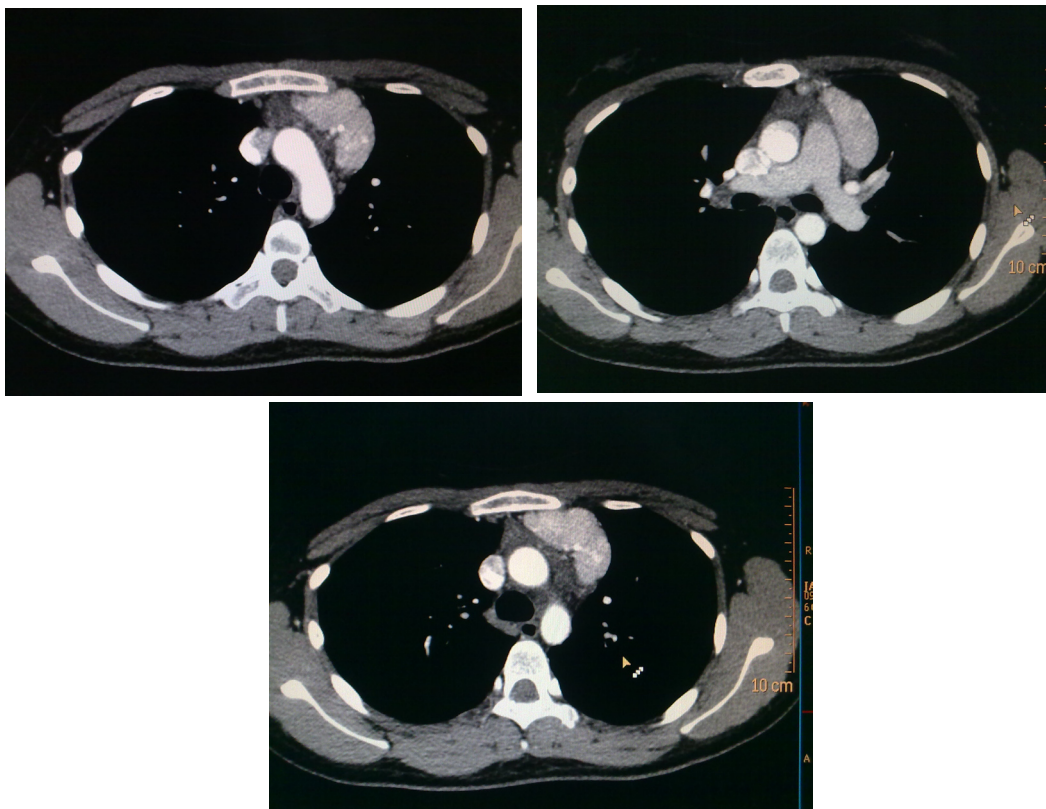


Figure 2. Chest CT scan images of the same patient showing an intensely enhancing, non-calcified, lobulated mass, measuring approximately 2.4 x 5.9 x 6.7 cm (AP x W x CC) in the left anterior mediastinum at the level of the aortic arch extending to the left lateral aspect of the main pulmonary artery.

arch extending to the left lateral aspect of the main pulmonary artery. (Figure 2)

An initial impression of a thymoma was made and the patient was scheduled for a thymectomy. The patient was preoperatively referred to the Neurology Service to rule out co-existence of Myasthenia Gravis.

The operative approach was via a median sternotomy. Intraoperatively, there was a 9 cm x 7 cm x 4 cm well-circumscribed lobulated mass adjacent to the left lobe of the thymus gland extending posteriorly to the innominate vein and left pulmonary artery. There was no evidence of infiltration of adjacent structures. The procedure done was excision of the anterior mediastinal mass including the thymus. The patient had an unremarkable postoperative course. She was immediately extubated postoperatively and started on progressive diet. The chest tube was removed on the second postoperative day and the patient was eventually discharged recovered on the 6th postoperative day.

The final histopathologic examination revealed nodal tissue with proliferation of follicles characterized by regressed transformed germinal centers. There is tight concentric layering of lymphocytes at the periphery of the follicles resulting in an onion-skin like appearance. The follicles showed marked vascular proliferation and hyalinization of the germinal centers. The intrafollicular stroma is otherwise prominent, with numerous hyperplastic vessels and admixture of plasma cells, eosinophils, and immunoblasts. Associated vascular proliferation is also present in the surrounding soft tissue. The histologic features were compatible with Castleman's disease, hyaline vascular type (angiofollicular lymph node hyperplasia). The thymus gland showed features of involution. There was no evidence of dysplasia or malignant transformation.

Discussion

Castleman's disease is a rare, benign disorder of the lymph nodes that should

be included in the differential diagnosis of anterior mediastinal masses. It is a lymphoproliferative disorder and is also known as "hamartoma, angiofollicular lymph node hyperplasia, benign giant lymphoma, giant lymph node hyperplasia, and follicular lymphoreticuloma."⁵ It is sometimes associated with other diseases such as human immunodeficiency virus (HIV) and human herpes virus 8 (HHV-8). It is sometimes associated with malignancies such as Kaposi's sarcoma (KS), non-Hodgkin's lymphoma, Hodgkin's lymphoma, and POEMS (polyneuropathy, organomegaly, endocrinopathy, monoclonal proteinemia and skin) syndrome.^{5,9,10}

It can occur anywhere in the body wherever there are lymph nodes but approximately 70% of the cases are located in the thorax, 14% in the neck, 12% in the abdomen and 4% in the axilla.¹⁴ The lesions are predominantly of two histologic types: the hyaline vascular type and the plasma cell type.⁵ Majority of these lesions are of the hyaline vascular type, which accounts for approximately 90% of cases and is most often a localized disease. Radiologic studies show that these masses typically appear as well-circumscribed mass in the visceral compartment of the mediastinum. These patients tend to be younger (median age, 23.5 years), to be asymptomatic, and to have a benign clinical course.⁶ "Surgical excision is curative, with a 5-year survival rate of 100%, although close follow-up is recommended due to reports of recurrence."⁶ The plasma cell variant, characterized by relatively few capillaries and the presence of mature plasma cells between the hyperplastic and germinal centers, usually presents with anemia, fever, fatigue, polyclonal hypergammaglobulinemia and bone marrow plasmacytosis.⁷⁻⁸

Castleman's disease can also be classified into two clinical forms, namely localized and multicentric. Those with localized disease have only one mediastinal compartment involvement, with no evidence of disease in an extrathoracic site. If more than one mediastinal compartment or if there is evidence of disease in an extrathoracic site, it is classified as disseminated Castleman's

disease.¹¹ Our patient presented with a multicentric form of the disease since there were lymphadenopathies noted in the neck and left supraclavicular area.

The etiology of Castleman's disease remains unknown. It may be due to infection (HHV-8), Autoimmunity or Cytokine dysregulation (IL-6).⁶

The histologic diagnosis of Castleman's Disease is usually made after the mass is excised; needle biopsy is not usually done because of low diagnostic accuracy, whereas, in thorascopic biopsy, there is a risk of bleeding due to the tumor's hypervascularity.¹²⁻¹³ The treatment for unicentric disease can either be surgery or radiotherapy if resection was incomplete or chemotherapy. For multicentric disease, treatment options include Steroids (60-70% ORR, 15% CR, usually not durable), Chemotherapy with Rituximab, or Auto BMT, Antivirals, and Anti-IL-6.

References

1. Castleman B, Iverson L, Menendez VP. Localized Mediastinal Lymph-Node Hyperplasia Resembling Thymoma. *Cancer* 1956, 9:822-830.
2. Palestro G, Turrini F, Pagano M, Chiusa L. Castleman's disease. *Adv Clin Path*, 3: 11-22, 1999.
3. Bowne WB, Lewis JJ, Filippa DA, Niesvizky R, Brooks AD, Burt ME, Brennan MF. The management of unicentric and multicentric Castleman's disease. *Cancer*, 85: 706-717, 1999.
4. Shroff VJ, Gilchrist BF, De Luca FG, McCombs HL, Wesselhoeft CW: Castleman's disease presenting as a pediatric surgical problem. *J Pediatr Surg*, 30: 745-747, 1995.
5. Keller AR, Hocholzer L, Castleman B. Hyaline vascular and plasma cell types of giant lymph node hyperplasia of the mediastinum and other locations. *Cancer* 1972; 29: 670-82.
6. Kim JH, Jun TG, Sung SW, et al. Giant lymph node hyperplasia (Castleman's disease) in the Chest. *Ann Thorac Surg* 1995; 59:1162-1165.
7. J ohkoh T, Mueller NL, Ichikadoh K, Nishimoto N, Yoshizaki K, et al. Intrathoracic Multicentric Castleman's disease: CT findings in 12 patients. *Radiology* 1998; 209:477-481.
8. Weisenbruger DD, Athawani BN, Winndberg CD, Rapaport H. Multicentric angiofollicular lymph node hyperplasia; a clinicopathologic study of 16 cases. *Hum Pathol* 1985;2:162-172.
9. Flendrig JA, Schillings PHM. Benign giant lymphoma: the clinical signs and symptoms. *Folia Med Neerl* 1969; 12:119.
10. Gaba AR, Stein RS, Sweet DL, Variakojis D. Multicentric giant lymph node hyperplasia. *Am J Clin Pathol* 1978; 69(1): 86- 90.
11. A Ahluwalia, K Saggarr, P Sandhu, V Kalia. Chest: Castleman disease of thorax. *Ind J Radiol Imag* 2005 15:2:232.
12. Ottavio Rena, Caterina Casadio, Giuliano Maggi. Castleman's disease: unusual intrathoracic localization. *Eur J Cardio-thorac Surg* 2001; 19: 519-21.
13. Peter A. Seirafi, Eric Ferguson, Fred H. Edwards. Thorascopic resection of Castleman's disease. *Chest* 2003; 123: 280-82.
14. Frizzera G, Massarelli G, Banks PM, Rosai J. A systemic lymphoproliferative disorder with morphological features of Castleman's Disease; Pathological findings in 15 patients. *Am J Surg Pathol* 1983; 7: 212-31.